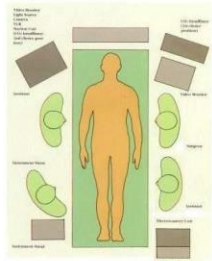
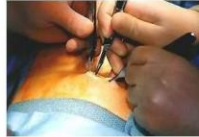

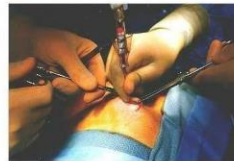# Laparoscopic Cholecystectomy



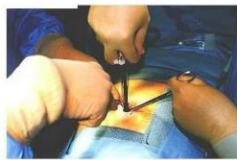Operative room setting



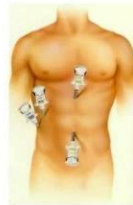Subumbilical skin incision



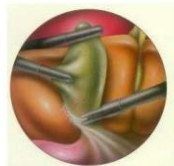Veress needle for insufflation



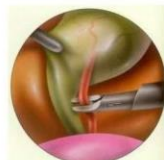First trocar insertion



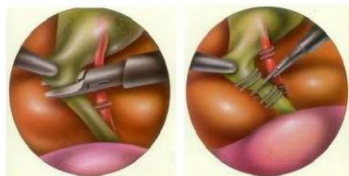
trocar insertions



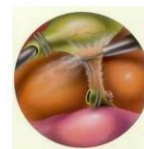Dissection of gall bladder



Clipping the cystic artery



Transection of the cystic duct



Dissection of the gall bladder from its bed



Comparison between conventional and laparoscopic method

## REFERENCE

Techniques in endosurgery, Ethicon Endo-surgery : Edward H. Phillips

<http://www.Laparoscopy.com-Welcome page>