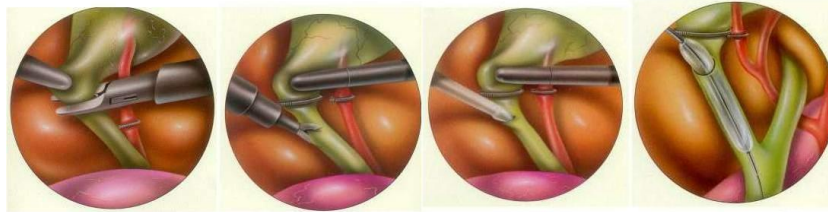


CBD Exploration

Transcystic duct common bile duct exploration

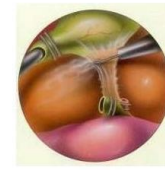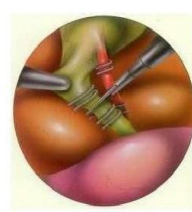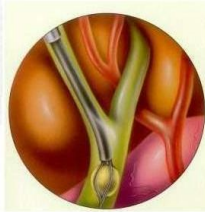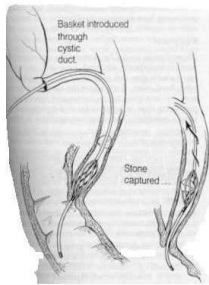


Clip the cystic duct

Partial cut

Intraoperative Cholangiography

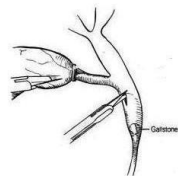
Balloon dilatation



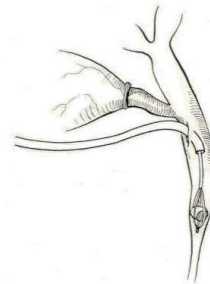
Stone removal by basket

Routine cholecystectomy

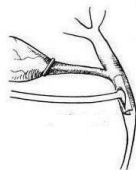Laparoscopic common bile duct exploration



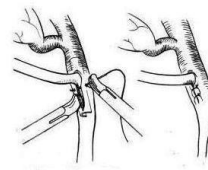
Small incision made in common bile duct



Stone entrapped in basket and removed



T-tube placed



T-tube sutured in place

REFERENCE

Techniques in endosurgery, Ethicon Endo-surgery; Edward H. Phillips

Minimally Invasive Surgery; John G. Hunter & Jonathan M. Sackier