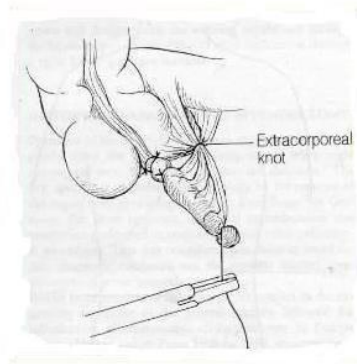
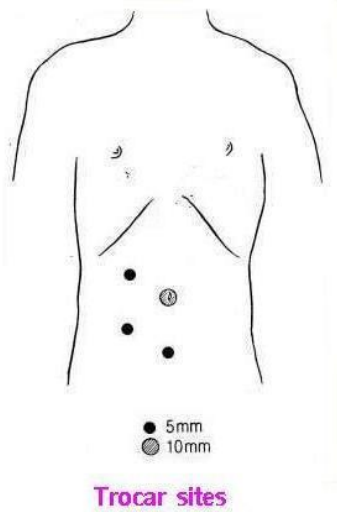


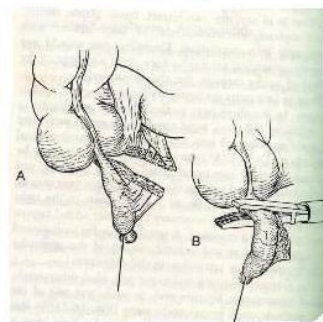
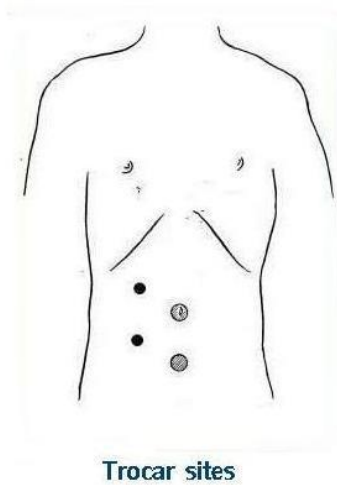
Laparoscopic Appendectomy

First method



Ligation of the mesoappendix , appendical base, distal part of the appendix and divide it between ligations and remove

Second method



Endostapler applications

REFERENCE

Minimally Invasive Surgery : John G. Hunter & Jonathan M. Sackier